

Are your patients with Diabetes struggling to heal their wounds?

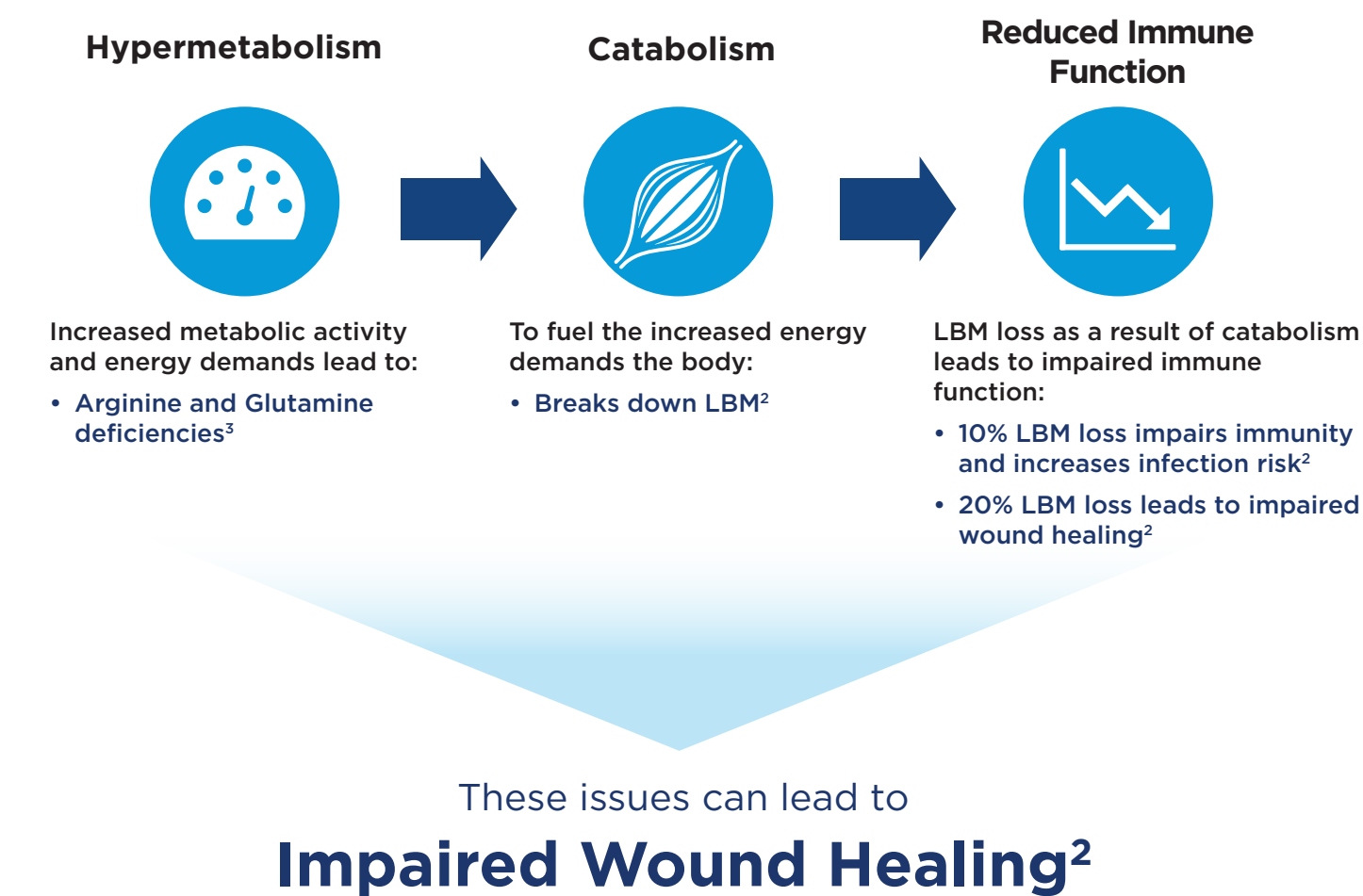


Juven[®]: A targeted amino acid nutrition therapy
Juven is clinically shown to support wound healing in 2 weeks^{1*}

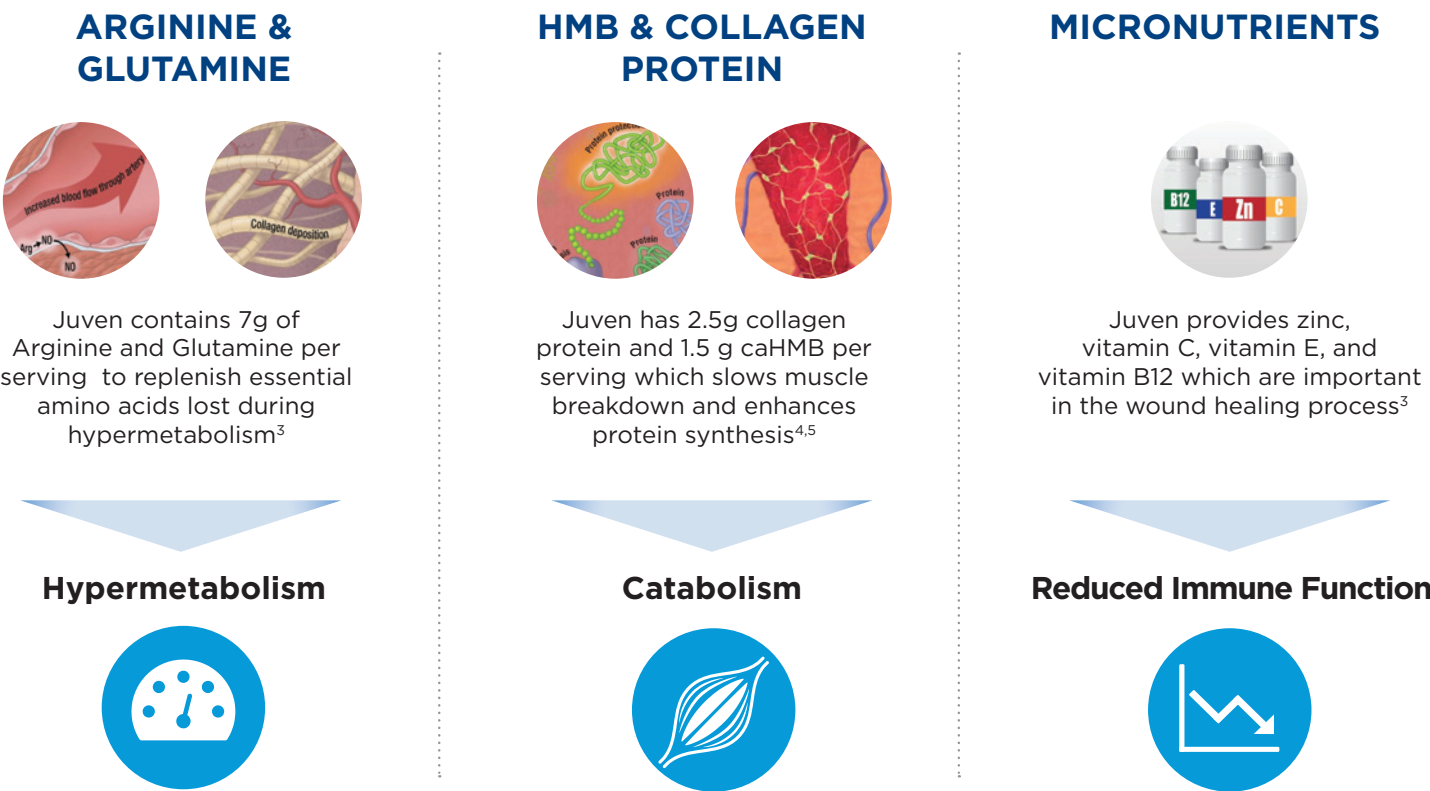
Juven
From the makers of **Ensure**[®]

Patients recovering from ulcers, surgeries, or traumatic conditions impacting lean body mass (LBM) may experience:²

For optimal wound healing, hypermetabolism, catabolism, and impaired wound healing should be addressed²



JUVEN HAS A UNIQUE BLEND OF KEY INGREDIENTS TO SUPPORT WOUND HEALING IN AS LITTLE AS 2 WEEKS:^{2*}



Complications increase with greater LBM loss ²	
% Loss of total LBM	Complications
10	Impaired immunity, increased infection
20	Decreased healing, weakness, infection, thinning of skin
30	Too weak to sit, pressure ulcers, pneumonia, wound healing stops
40	Death—usually due to pneumonia

Juven increases the likelihood a diabetic foot ulcer (DFU) will heal by

70%

relative to a placebo if patients are at risk for malnutrition⁶

Juven increases the likelihood a DFU will heal by

66%

relative to a placebo if patients have poor blood circulation in their feet⁶



Recommend **2 packets of Juven per day** to support wound healing

In the absence of preexisting LBM loss. Adapted from Demling RH: Nutrition, anabolism, and the wound healing process: an overview. *Eplasty*. 2009;9:e9.

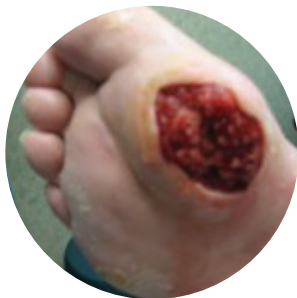Juven Supplementation in a Diabetic Foot Ulcer Patient – A Juven Case Study

Overview

Charles, a 62-year-old male, had a 20-year history of diabetes mellitus when he developed a diabetic foot ulcer with osteomyelitis.

In January, Charles sought medical attention after a crack on the bottom of his foot developed into a lesion.

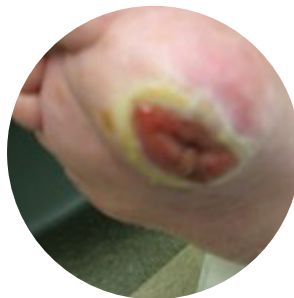- Tissue around the lesion was inflamed and necrotic
- Four weeks later, his wound-care team administered a debriding treatment
- The DFU worsened and Charles developed osteomyelitis
- Charles was treated with IV antibiotics for the following 9 months



August—Before Juven therapy

Wound-care team decided that the ulcer required a second debridement. After the procedure, wound measured 6.35 cm (L) x 5.08 cm (W) and 2.54 cm (H).

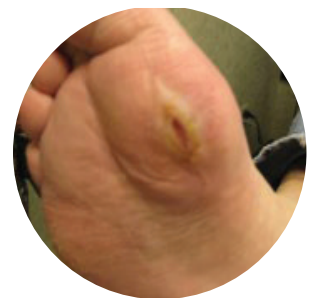- Physician directed Charles to clean the wound, change the dressing daily, and take an oral antibiotic (Levofloxacin)
- In spite of the debridement, good home care, and adequate nutrition, the wound continued to worsen
- Consulting physician recommended below-the-knee amputation and wound-care team recommended hyperbaric oxygen therapy



October—After 2 weeks of Juven therapy

Faced with potential amputation and hyperbaric oxygen therapy, Charles's doctor suggested that he add 2 packets of Juven to his daily diet.

- Charles mixed 1 packet of Juven with 8-10 oz of water, twice per day
- After 2 weeks, Charles noticed his wound beginning to heal
- Charles continued to take Juven every morning and night for 6 weeks



December—After 14 weeks of Juven therapy

Wound had reached remodeling phase.

- Charles returned to the wound-care center for a follow-up visit
- Ulcer surface had diminished to 3.81 cm (L) x 1.27 cm (W)

* Studied in healthy elderly adults in a wound healing model, taking two servings per day

References: **1.** Williams et al. Effects of a specialized amino acid mixture on human collagen deposition. *Ann Surg* 2002;236:369-375. **2.** Demling RH: Nutrition, anabolism, and the wound healing process: an overview. *Eplasty*. 2009;9:e9. **3.** Joseph Molnar: *Nutrition and Wound Healing*. CRC Press. 2006. **4.** Wilson GJ, Wilson JM, Manninen AH. Effects beta-hydroxy-beta-methylbutyrate (HMB) on exercise performance and body composition across varying levels of age, sex, and training experience: a review. *Nutr Metab (Lond)*. 2008;5:1. **5.** Nissen SL, Abumrad NN. Nutritional role of the leucine metabolite beta-hydroxy-beta-methylbutyrate (HMB). *J Nutr Biochem*. 1997;8(6):300-311. **6.** Armstrong DG, Hanft JR, Driver VR, et al. Effect of oral nutritional supplementation on wound healing in diabetic foot ulcers: a prospective randomized controlled trial. *Diabet Med*. 2014; 31:1069-1077.

Use under medical supervision in addition to a complete, balanced diet.